

REGION-WISE GRAY MATTER VOLUME ALTERATIONS IN BRAIN OF ADOLESCENTS WITH ATTENTION DEFICIT HYPERACTIVE DISORDER : A VOXEL BASED MORPHOMETRIC ANALYSIS

RAMESH M.G., KIRANMAI S. RAI^{1*}

¹*Departments of Physiology and Neurosciences,
KMC-International Center,
Manipal University, Manipal, Karnataka, India*

(Received on June 11, 2012)

Abstract : Attention Deficit Hyperactive Disorder (ADHD) is a behavioral neuropsychiatric disorder affecting an estimated 5% of school-age children worldwide with symptoms persisting into adulthood in 80% of cases. Presently clinical diagnosis and treatment of ADHD relies on behavioral disturbances than on detecting underlying defective brain regions. Therapeutic outcome in treatment of ADHD may be more positive if defective brain region in clinically diagnosed ADHD is detected by voxel based morphometric (VBM) analysis that measures voxel-wise global and regional focal volume differences in structural magnetic resonance images (sMRI) of brain. This study was designed to detect any region-specific gray matter (GM) volume defects in sMRI of ADHD adolescents by VBM analysis. Thirty sMRI datasets matched for sex, handedness of adolescents aged between 11.66 and 20.47 years (mean age 16.27±2.48 years) obtained from NeuroImage webpage, were selected (Control n=15; ADHD combined type n=15). These sMRI were analyzed by VBM technique and compared using statistical parametric mapping (SPM). Significant regional GM volume deficits (P<0.05) was specifically identified in left cuneus and middle occipital gyrus in ADHD, after voxel-wise false discovery rate correction over the whole brain compared to matched controls. Deficit of GM volume in occipital cortex detected by VBM analysis in ADHD children, suggests defects of visual processing affecting attention mechanisms.

Key words : ADHD occipital gyrus sMRI VBM analysis

INTRODUCTION

Attention Deficit Hyperactive Disorder (ADHD) is a behavioral neuropsychiatric disorder characterized by hyperactivity,

inattention or both (combined type) (1) affecting up to 1 in 20 children in the USA (2). The estimated prevalence of ADHD in school-age children worldwide is approximately 5%. However, the prevalence

*Corresponding author : Kiranmai S. Rai PhD, Professor of Physiology and Neurosciences, KMC-International Center, Manipal University, Manipal – 576 104, Udupi District, Karnataka State, India; Phone: +918202933020 (Office); Fax : +918202933002; Email: kiranmai_rai2001@yahoo.com; kiranmai.raim@manipal.edu

of ADHD varies according to the diagnostic criteria used, geographical location and various other factors (3). The estimated prevalence of school-going children with ADHD in India is about 12.2%. A wide range of behavioral and cognitive impairment are found in ADHD individuals, which includes deficits in working memory, inhibitory control, altered motivation, motor restlessness and poor performance. ADHD is associated with significant comorbidity including anxiety, and bipolar disorders (4-6). In approximately 80% of ADHD children, symptoms starts in childhood and frequently persists into adolescence through adulthood (7).

Typically screening/assessment of ADHD involves more than one professional, since there is no single test to confirm ADHD. Screening tests include thorough medical and family history, general physical, neurological examination, comprehensive questionnaires/tools to parents, teachers and children to rule-out symptoms of anxiety, depression and or learning disabilities/other neurological problems, psychological tests to measure IQ, social and emotional behaviors. Subsequent to behavioral screening tests, various imaging tests like single photon emission computed tomography (SPECT) (8), functional magnetic resonance imaging (fMRI), structural magnetic resonance imaging (sMRI) (9, 10) and quantitative electroencephalography (qEEG) (11), in addition to genetic and genomic tests (12) may be used to detect any defect in the brain regions. Thus, a more accurate diagnosis of specific regional defects in gray matter (GM) of brain in ADHD and accuracy in treatment protocol requires state-of-the-art NeuroImaging techniques and analysis.

MRI analysis studies show that ADHD is associated with alterations in brain structure, particularly a decrease in total cerebral volume (13) and other studies on ADHD have also shown an association with anterior cingulate dysfunction which plays an important role in attention (14). Current neurobiological models of ADHD postulate fronto-striatal dysfunction as a key component of the disorder. Evidence from NeuroImaging studies shows the involvement of fronto-striatal circuit in ADHD (15). In a comparative study, the right caudate nucleus area in the ADHD group was found to be larger (16). However, studies comparing children with and without ADHD have found differences in the size and symmetry of the caudate nuclei (17).

The underlying specific regional defects in grey matter of brain in ADHD can be more accurately detected and gauged by using voxel based morphometric (VBM) analysis, an advanced NeuroImaging analytical technique that measures voxel-wise changes of global and regional volume differences in sMRI, using statistical parametric mapping (SPM).

Thus, the objective of the present comparative study was to detect any region-specific GM volume alterations in brain sMRI from control adolescents matched for age, sex and handedness and those diagnosed with combined type of ADHD, by use of VBM analytical technique.

MATERIAL AND METHODS

sMRI datasets

Forty-eight, three dimensional T1

weighted sMRI datasets of adolescent children aged between 11.66 and 20.47 years (mean age 16.27 ± 2.48 years) from the NeuroImage webpage (http://fcon_1000.projects.nitrc.org/indi/adhd200)- International NeuroImaging Data sharing Initiative (INDI), were obtained. INDI allows contributing or downloading MRI datasets, which are permitted to be used for publication under Creative Commons License (Attribution Non-Commercial license). Of forty-eight sMRI datasets of adolescent children, thirty datasets for age, sex and handedness were matched and selected (Table I) for comparative analysis of regional GM volume by VBM analytic technique. The selected data sets consist of 15 combined type ADHD and 15 typically developing children, designated as controls. The study was approved by our Institutional Research and Ethics Committee.

Diagnosis of ADHD

As given in the downloaded dataset, diagnosis of ADHD was based on parent and child responses to the Schedule of Affective Disorders and Schizophrenia for Children—Present and Lifetime Version (KSADS-PL) and the Conner's Parent Rating Scale-

Revised, Long version (CPRS-LV). Psycho stimulant drugs were withheld at least 24 hours before scanning, and other psychotropic medications were withheld at least 3 days before scanning. Subjects with absence of any Axis-I psychiatric diagnoses per parent and child KSADS-PL interview, as well as T-scores below 60 for all the CPRS-R: LV ADHD summary scales were included as control. Estimates of full scale intelligent quotient (FSIQ) above 80, and absence of other chronic medical conditions were required for all children. Intelligence was evaluated with the Wechsler Abbreviated Scale of Intelligence (WASI). (http://fcon_1000.projects.nitrc.org/indi/adhd200)

Image acquisition

According to the information obtained in the downloaded dataset, all thirty sMRI of each subject were taken using magnetic field intensity, with high resolution; Magnetom Symphony (Avanto syngo MR B17) scanner; sequence, T1 magnetization-prepared rapid acquisition of gradient echo; TR, 2730 ms; TE, 2.95 ms; TI, 1000 ms; voxel size, $1 \times 1 \times 1 \text{ mm}^3$; flip angle, 7° ; sagittal slices per slab, 176).

VBM analysis

In this study, by using these downloaded dataset, VBM analysis was performed. It is a method for investigating neuroanatomical alterations in an unbiased, objective way. VBM analysis involves measurement of voxels in the images, from which differences in volume of brain regions, especially GM can be obtained. Significant difference in the volume of brain regions is established by statistically comparing between two or more

TABLE I: Comparison of age, sex and handedness of the patients.

	<i>Control</i> <i>n=15</i>	<i>ADHD</i> <i>Patients</i> <i>n=15</i>	<i>P-</i> <i>value</i>
Age [†]	16.72 \pm 2.55	16.8 \pm 2.5	>0.05
Sex (Male : Female) [‡]	4:11	4:11	>0.05
Handedness (Right : Left) [§]	14:1	14:1	>0.05

[†]Comparison using independent sample t test, Values represented as Mean \pm SD; [‡],[§]Comparison using chi square test.

regions of different experimental groups (18). VBM analysis was done by using VBM8 tool box software version 429 (cf. <http://dbm.neuro.unijena.de/vbm8>) and SPM8 software version 4667 (cf. <ftp://ftp.fil.ion.ucl.ac.uk/spm>) installed in MATLAB software version 7.12.0.635 (R2011a).

All the sMRI images used in this analysis were manually reoriented by setting anterior commissure as origin.

(a) Preprocessing

Since the present study was performed by using sMRI brain images from adolescents, Tissue Probability Map (TPM) was customized, appropriate for spatial normalization of sMRI data, by using the TOM8 toolbox version 9 (cf. <https://irc.cchmc.org/software/tom/agreement.php>). All other parameters remained default except TPM. Preprocessing of all reoriented T1 images resulted in modulated non-linear dartel warped segmented volumes of GM, WM and CSF and values for global volume of GM, WM and CSF for each image was automatically obtained.

(b) Quality check

By using VBM8 check quality option, all segmented T1 images were checked for image quality and presence of any artifact. All images selected were of good in quality and without artifacts.

(c) Smoothing

For VBM statistical analysis, Gaussian kernel of 8-mm full-width at half maximum (FWHM) was used to smooth the images.

(d) Statistical analysis

The final probability maps were obtained and automatically analyzed by voxel-wise testing using a two sample *t*-test with intra cranial volume as covariate in SPM8, to measure group differences in regional GM volumes. Effect of nuisance variables in selected sMRI used in this analysis were automatically removed by matching for age, sex and handedness of subjects. XJ View software version 8.4 (cf. <http://www.alivelearn.net/xjview8/>) was used for further analysis of results and all observed *p*-value distributions were corrected by applying voxel wise false discovery rate (voxel-FDR) ($P < 0.05$). FDR is a new approach to multiple comparison problems and studies by Chumbley J et al (2010) has cited that voxel-FDR is more sensitive than extent-FDR, which in turn is more sensitive than peak-FDR and additionally conventional voxel-FDR discovers more local peaks than conventional FWE. Instead of controlling chance of any false positives (as in Bonferroni or random field methods), voxel-FDR controls the expected proportion of false positives among supra-threshold voxels. Values for GM, WM, and CSF volumes for each subject were automatically generated by this method and total brain volume/intracranial volume (TBV/ICV) for each subject was obtained by adding values of GM, WM and CSF volumes. SPSS software version 16 for paired *t* test to compare values of GM, WM, and CSF volume of control and ADHD patients was used in this study since all selected sMRI were matched for age, sex and handedness.

RESULTS

A mean difference in global GM, WM and

CSF volumes were found in sMRI brain images of ADHD patients when compared with the same in controls as shown in Fig. 1. Additionally, a significant decrease ($P < 0.05$) after correction for voxel-FDR was found in region-specific GM volumes (Table II) of sMRI brain images from ADHD children as compared to the same in controls, particularly in regions like the occipital,

cingulate, superior frontal cortices and other regions (Fig. 4), but also an increase in GM volume in the right thalamus (uncorrected $P < 0.001$) (Fig. 3, Table III) which was not significant with voxel-wise FDR correction.

A significant deficit in the left cuneus and left middle occipital gyrus (Fig. 2) in addition to other regions detected in this

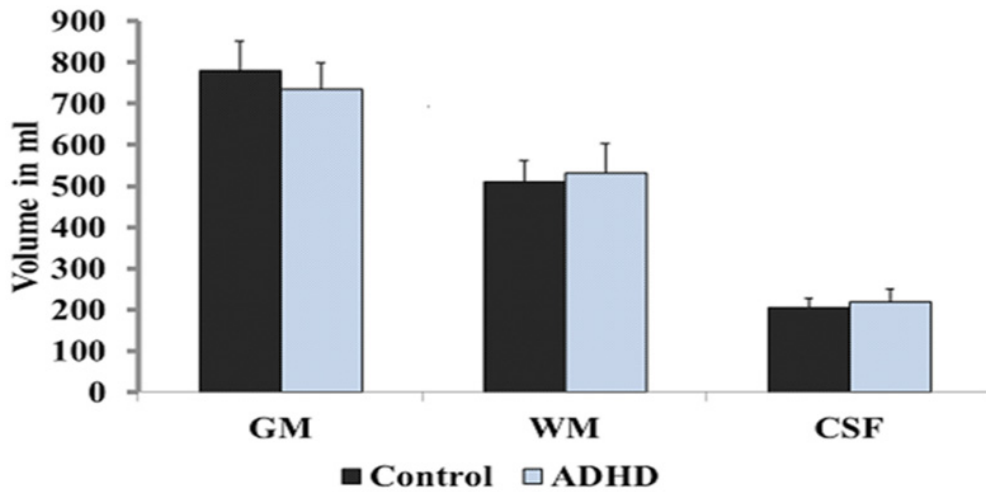


Fig. 1: Comparison of global regional volume between ADHD patients ($n=15$) and controls ($n=15$). GM-gray matter; WM-white matter; CSF-cerebro spinal fluid.

TABLE II: Region specific GM volume deficits in ADHD compared to controls [$n=15$ /group].

Brain regions	BA	Coordinates (MNI) [†]			Number of voxels in cluster	t-score [‡]
		X	Y	Z		
Left cingulate gyrus	–	–17	–40	36	2965	5.65*
Right middle cingulate gyrus	24	3	–13	39	2965	5.14*
Left superior frontal gyrus	–	–23	56	31	176	5.29*
Left medial superior frontal gyrus	9	0	54	5	212	5.10*
Right medial superior frontal gyrus	9	3	33	39	125	4.96*
Left temporal lobe - sub-gyrus	–	–38	–63	4	264	4.89*
Left middle occipital gyrus	–	–41	–75	4	264	4.76*
Left cuneus	18	–12	–88	12	125	4.66*
Left superior temporal gyrus	39	–45	–61	28	183	4.42*
Left temporal supra marginal gyrus	–	–50	–55	24	183	4.01*

[†]MNI-Montreal Neurological Institute coordinates of peak difference, [‡]t-score indicates significant deficits after false discovery rate correction over the whole brain. BA – Bradman area, * $P < 0.05$.

TABLE III: Increase in GM volume of right thalamus in ADHD compared to controls (n=15/group).

Brain regions	BA	Coordinates (MNI) [†]			Number of voxels in cluster	t-score [‡]
		X	Y	Z		
Right Thalamus-Sub lobar region	-	23	-33	-2	36	3.98*

[†]MNI-Montreal Neurological Institute coordinates of peak difference. [‡]t-score indicates significant deficits. BA - Bradman area, *P<0.001 (Uncorrected).

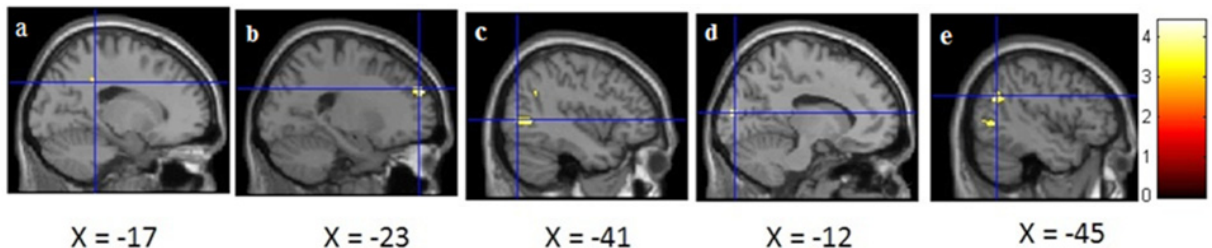


Fig. 2: Representative sMRI sagittal views of ADHD patients showing regional GM volume deficits in the a. Left cingulate gyrus (X=-17), b. left superior frontal cortex (X=-23), c. Left middle occipital gyrus (X=-41), d. Left cuneus (X=-12), and e. Left superior temporal gyrus (X=-45). Color bar indicates t-score values; t-score values >0 indicates a deficit and <0 indicates an increase in GM volume.

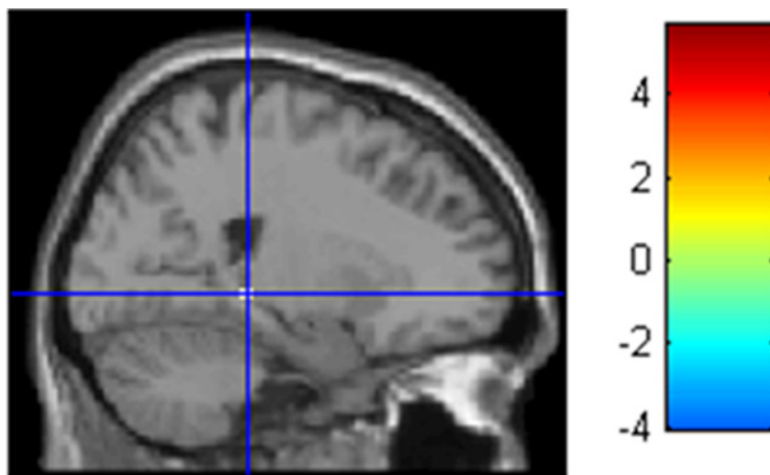


Fig. 3: Representative sMR sagittal image of ADHD patient showing increase in GM volume at the right thalamus - sublobar region (X = 23). Color bar indicates t-score values; t-score values >0 indicates a deficit and <0 indicates an increase in GM volume.

study suggests involvement of occipital cortex also, in the development of behavioral signs and symptoms in ADHD children.

DISCUSSION

A deficit in the left middle occipital cortex

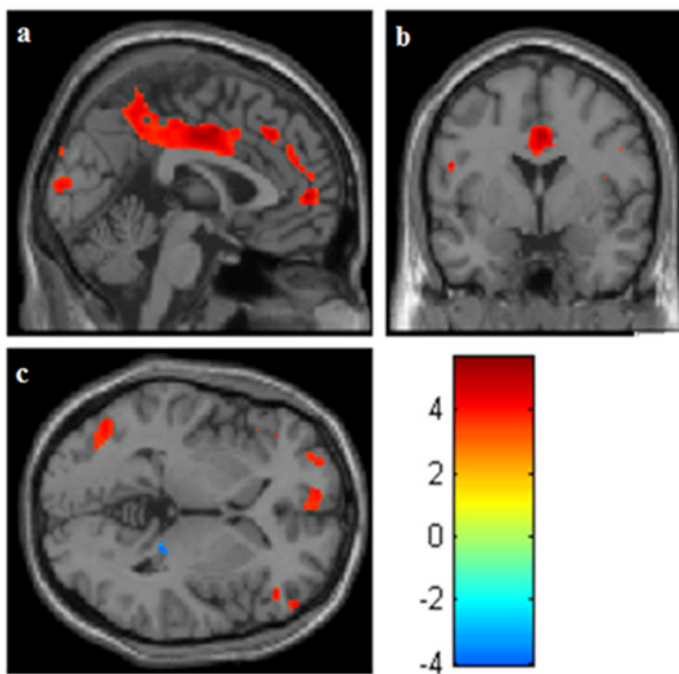


Fig. 4: Representative sMRI a. sagittal view, b. coronal view, c. axial view overlapped with single subject MNI template showing overall regional GM volume deficits in ADHD patients compared to controls. Color bar indicates t-score values; t-score values >0 indicates a deficit and <0 indicates an increase in GM volume. Region-wise gray matter volume alterations in brain of adolescents with attention deficit hyperactive disorder: A voxel based morphometric analysis.

and left cuneus region was detected by VBM technique in addition to other regions in this study, suggesting involvement of occipital region in development of signs and symptoms of attention deficit in combined type ADHD. Though behavioral data of the selected adolescent ADHD subjects in this study was not available from the downloaded dataset, the detected deficits in volumes of occipital and cuneus regions in these ADHD subjects suggests early signs of abnormalities in visual sensory processing, a possible cause for impairment in attention mechanism. Alternately, few NeuroImaging studies specifically indicate increase in occipital gray matter (GM) volume in ADHD (19, 20), though in the same studies regional volume deficits in other regions of brain was

observed.

In support of our findings, Ahrendts et al (21) described visual cortex abnormalities in sMRI of adults and Durston S et al (22) observed left occipital GM and WM volume reduction in adolescents with ADHD and they suggest that these abnormalities may be related to pathophysiology of ADHD. Moreover, EEG studies on children with ADHD by Nazari et al (23) suggested early deficits in electrical activity and visual sensory integration in occipital cortex. Alternately, other studies on children with ADHD did not find EEG correlations for cued targets, suggesting a functional disconnection between frontal and occipital cortex in them (24).

In addition deficits in GM volume of bilateral cingulate gyrus and bilateral medial superior frontal regions in ADHD were also found in the present study. Many studies report that these regions are involved in alerting, executive attention functions and behavioral inhibition, which are necessary for working memory. These regions are also important in higher-level cognitive functions but basically deals with primary stimuli such as reward (25). A decrease in GM volume of left temporal region that is reported to be associated with verbal strategies was also observed in the present study similar to recent studies on ADHD children with history of low birth weight by Sasayama et al (26).

Alternately, an increase in GM volume of sub-lobar region of right thalamus was also found in ADHD subjects, consistent to other studies reporting regional increase in pulvinar volume following stimulant drug treatment (27). Studies by Cortese et al (28) suggest that low iron in the thalamus may contribute to ADHD pathophysiology.

Along with regional alterations, global GM volume deficits were also found in the present study. Individuals with ADHD tend to activate a more diffuse, wider system of brain region to perform a task (14, 29-31) whereas patterns of functional brain activity becomes less diffuse and more focal with maturation and is associated with development in children (20). Similar GM volume deficits have been reported in various other sMRI imaging studies (13, 30) on ADHD patients. The study by Castellanos et al. (32) on brain development in ADHD during childhood and adolescence report that

developmental trajectories of all structures, except caudate showed smaller volumes suggesting that genetic and/or early environmental influences are fixed, non-progressive, and unrelated to stimulant treatment. Brain-imaging data in adults suggest that the pathophysiological principles of ADHD do not profoundly change from childhood and adolescence to adulthood, regardless of some changes in psychopathology (33).

Other meta-analytical studies on sMRI of ADHD children have identified right putamen/globus pallidus regional GM reduction indicating involvement offronto-striatal circuit (34, 35). Similar changes were not observed in the present study.

Conclusion

In conclusion the present study highlights the importance for VBM analysis of sMRI images clinically diagnosed with ADHD, as an advanced NeuroImaging analytical tool to detect any specific GM volume alterations of brain regions involved in attention and working memory function. Moreover, this study also reports detecting specific deficits in GM volume in the occipital region of adolescents with combined type ADHD, suggesting possible defects in visual processing and shorter attention span. However, to confirm this finding, additional detailed VBM analytic studies correlated with behavioral data need to be conducted on a larger cohort of sMRI from adolescents with combined type ADHD. Thus, VBM studies may be helpful in detecting specific focal gray matter (GM) volume deficits in regions of brain sMRI of ADHD, possibly aiding for appropriate treatment protocols.

ACKNOWLEDGEMENTS

This VBM analytic study was carried out using downloaded datasets from the International NeuroImaging Data-sharing Initiative (INDI), NeuroImage webpage (http://fcon_1000.projects.nitrc.org/indi/

adhd200). INDI allows contributing or downloading MRI datasets, which are permitted to be used for publication under Creative Commons License (Attribution Non-Commercial license). The authors gratefully acknowledge the permission given to use these downloaded MRI datasets for publication.

REFERENCES

1. Krain AL, Castellanos FX. Brain development and ADHD. *Clin Psychol Rev* 2006; 26(4): 433–444.
2. Faraone SV, Sergeant J, Gillberg C, Biederman J. The worldwide prevalence of ADHD: is it an American condition? *World Psychiatry* 2003; 2(2): 104–113.
3. Polanczyk G, de Lima MS, Horta BL, Biederman J, Rohde LA. The worldwide prevalence of ADHD: a systematic review and meta-regression analysis. *Am J Psychiatry* 2007; 164(6): 942–948.
4. Biederman J, Faraone SV, Wozniak J, Mick E, Kwon A, Aleardi M. Further evidence of unique developmental phenotypic correlates of pediatric bipolar disorder: findings from a large sample of clinically referred preadolescent children assessed over the last 7 years. *J Affect Disord* 2004; 82 Suppl 1: S45–S58.
5. Biederman J, Kwon A, Wozniak J, Mick E, Markowitz S, Fazio V *et al.* Absence of gender differences in pediatric bipolar disorder: findings from a large sample of referred youth. *J Affect Disord* 2004; 83(2-3): 207–214.
6. Jaideep T, Reddy YC, Srinath S. Comorbidity of attention deficit hyperactivity disorder in juvenile bipolar disorder. *Bipolar Disord* 2006; 8(2): 182–187.
7. Hesslinger B, Tebartz van Elst L, Thiel T, Haegele K, Hennig J, Ebert D. Fronto-orbital volume reductions in adult patients with attention deficit hyperactivity disorder. *Neurosci Lett* 2002; 328(3): 319–321.
8. Amen DG, Carmichael BD. High-resolution brain SPECT imaging in ADHD. *Ann Clin Psychiatry* 1997; 9(2): 81–86.
9. Schneider M, Retz W, Coogan A, Thome J, Rosler M. Anatomical and functional brain imaging in adult attention-deficit/hyperactivity disorder (ADHD)—a neurological view. *Eur Arch Psychiatry Clin Neurosci* 2006; 256 Suppl 1: i32–i41.
10. Pastura G, Mattos P, Gasparetto EL, Araujo AP. Advanced techniques in magnetic resonance imaging of the brain in children with ADHD. *Arq Neuropsiquiatr*; 69(2A): 242–252.
11. Ogrim G, Kropotov J, Hestad K. The quantitative EEG theta/beta ratio in attention deficit/hyperactivity disorder and normal controls: sensitivity, specificity, and behavioral correlates. *Psychiatry Res* 2012; 198(3): 482–488.
12. Faraone SV, Perlis RH, Doyle AE, Smoller JW, Goralnick JJ, Holmgren MA *et al.* Molecular genetics of attention-deficit/hyperactivity disorder. *Biol Psychiatry* 2005; 57(11): 1313–1323.
13. Carmona S, Vilarroya O, Bielsa A, Tremols V, Soliva JC, Rovira M *et al.* Global and regional gray matter reductions in ADHD: a voxel-based morphometric study. *Neurosci Lett* 2005; 389(2): 88–93.
14. Bush G, Frazier JA, Rauch SL, Seidman LJ, Whalen PJ, Jenike MA *et al.* Anterior cingulate cortex dysfunction in attention-deficit/hyperactivity disorder revealed by fMRI and the Counting Stroop. *Biol Psychiatry* 1999; 45(12): 1542–1552.
15. McAlonan GM, Cheung V, Cheung C, Chua SE, Murphy DG, Suckling J *et al.* Mapping brain structure in attention deficit-hyperactivity disorder: a voxel-based MRI study of regional grey and white matter volume. *Psychiatry Res* 2007; 154(2): 171–180.
16. Mataro M, Garcia-Sanchez C, Junque C, Estevez-Gonzalez A, Pujol J. Magnetic resonance imaging measurement of the caudate nucleus in

- adolescents with attention-deficit hyperactivity disorder and its relationship with neuropsychological and behavioral measures. *Arch Neurol* 1997; 54(8): 963–968.
17. Schrimsher GW, Billingsley RL, Jackson EF, Moore BD, 3rd. Caudate nucleus volume asymmetry predicts attention-deficit hyperactivity disorder (ADHD) symptomatology in children. *J Child Neurol* 2002; 17(12): 877–884.
 18. Ashburner J, Friston KJ. Voxel-based morphometry—the methods. *Neuroimage* 2000; 11(6): 805–821.
 19. Sowell ER, Thompson PM, Welcome SE, Henkenius AL, Toga AW, Peterson BS. Cortical abnormalities in children and adolescents with attention-deficit hyperactivity disorder. *Lancet* 2003; 362(9397): 1699–1707.
 20. Wang J, Jiang T, Cao Q, Wang Y. Characterizing anatomic differences in boys with attention-deficit/hyperactivity disorder with the use of deformation-based morphometry. *AJNR Am J Neuroradiol* 2007; 28(3): 543–547.
 21. Ahrendts J, Rusch N, Wilke M, Philipsen A, Eickhoff SB, Glauche V *et al.* Visual cortex abnormalities in adults with ADHD: a structural MRI study. *World J Biol Psychiatry* 2011; 12(4): 260–270.
 22. Durston S, Hulshoff Pol HE, Schnack HG, Buitelaar JK, Steenhuis MP, Minderaa RB *et al.* Magnetic resonance imaging of boys with attention-deficit/hyperactivity disorder and their unaffected siblings. *J Am Acad Child Adolesc Psychiatry* 2004; 43(3): 332–340.
 23. Nazari MA, Berquin P, Missonnier P, Aarabi A, Debatisse D, De Broca A *et al.* Visual sensory processing deficit in the occipital region in children with attention-deficit/hyperactivity disorder as revealed by event-related potentials during cued continuous performance test. *Neurophysiol Clin* 2010; 40(3): 137–149.
 24. Mazaheri A, Coffey-Corina S, Mangun GR, Bekker EM, Berry AS, Corbett BA. Functional disconnection of frontal cortex and visual cortex in attention-deficit/hyperactivity disorder. *Biol Psychiatry* 2010; 67(7): 617–623.
 25. Knutson B, Fong GW, Bennett SM, Adams CM, Hommer D. A region of mesial prefrontal cortex tracks monetarily rewarding outcomes: characterization with rapid event-related fMRI. *Neuroimage* 2003; 18(2): 263–272.
 26. Sasayama D, Hayashida A, Yamasue H, Harada Y, Kaneko T, Kasai K *et al.* Neuroanatomical correlates of attention-deficit-hyperactivity disorder accounting for comorbid oppositional defiant disorder and conduct disorder. *Psychiatry Clin Neurosci* 2010; 64(4): 394–402.
 27. Ivanov I, Bansal R, Hao X, Zhu H, Kellendonk C, Miller L *et al.* Morphological abnormalities of the thalamus in youths with attention deficit hyperactivity disorder. *Am J Psychiatry* 2010; 167(4): 397–408.
 28. Cortese S, Azoulay R, Castellanos FX, Chahard F, Lecendreux M, Chechin D *et al.* Brain iron levels in attention-deficit/hyperactivity disorder: A pilot MRI study. *World J Biol Psychiatry* 2012; 13(3): 223–231.
 29. Durston S. A review of the biological bases of ADHD: what have we learned from imaging studies? *Ment Retard Dev Disabil Res Rev* 2003; 9(3): 184–195.
 30. Schweitzer JB, Faber TL, Grafton ST, Tune LE, Hoffman JM, Kilts CD. Alterations in the functional anatomy of working memory in adult attention deficit hyperactivity disorder. *Am J Psychiatry* 2000; 157(2): 278–280.
 31. Tamm L, Menon V, Ringel J, Reiss AL. Event-related fMRI evidence of frontotemporal involvement in aberrant response inhibition and task switching in attention-deficit/hyperactivity disorder. *J Am Acad Child Adolesc Psychiatry* 2004; 43(11): 1430–1440.
 32. Castellanos FX, Lee PP, Sharp W, Jeffries NO, Greenstein DK, Clasen LS *et al.* Developmental trajectories of brain volume abnormalities in children and adolescents with attention-deficit/hyperactivity disorder. *JAMA* 2002; 288(14): 1740–1748.
 33. Almeida Montes LG, Ricardo-Garcell J, Barajas De La Torre LB, Prado Alcantara H, Martinez Garcia RB, Fernandez-Bouzas A *et al.* Clinical correlations of grey matter reductions in the caudate nucleus of adults with attention deficit hyperactivity disorder. *J Psychiatry Neurosci* 2010; 35(4): 238–246.
 34. Yang H, Wu QZ, Guo LT, Li QQ, Long XY, Huang XQ *et al.* Abnormal spontaneous brain activity in medication-naïve ADHD children: A resting state fMRI study. *Neurosci Lett* 2011; 502(2): 89–93.
 35. Ellison-Wright I, Ellison-Wright Z, Bullmore E. Structural brain change in Attention Deficit Hyperactivity Disorder identified by meta-analysis. *BMC Psychiatry* 2008; 8: 51.